

# Impacted maxillary canines and their relationship with lateral incisor resorption: a cone beam computed tomography (CBCT) study

Hakan Yilmaz,\* Fethiye Cakmak Ozlu,† Murat Icen+ and Erdi Icen‡

Department of Orthodontics, Faculty of Dentistry, Istanbul Okan University, Istanbul,\* Department of Orthodontics, Faculty of Dentistry, Ondokuz Mayıs University, Samsun,† Oral Maxillofacial Radiology Department, Faculty of Dentistry, Nevşehir Hacı Bektaş Veli University, Nevşehir+ and Private Practice, Istanbul,‡ Turkey

*Objective:* The spatial position of a canine can affect the level of proximal root resorption and the success of orthodontic treatment. The aim of this study was to examine the mesiodistal and vertical position of impacted maxillary canines and to assess their relationship with the lateral incisor by using cone beam computed tomography (CBCT).

*Material and method:* One hundred and sixty-nine CBCT scans of patients presenting with maxillary impacted canines were included in the study. The buccopalatal, mesiodistal (classified as sectors I, II, III, IV from distal to mesial) and vertical (cervical, middle, apical) position of the maxillary impacted canines were determined. The positional effect on the morphology (width, length, and depth) and resorption was assessed on the roots of the maxillary lateral incisors. Obtained data were statistically analysed by using Student *t* test, the Mann Whitney *U* and Chi-Square tests.

*Results:* Of the maxillary impacted canines, the 34.72% that had associated resorption on the adjacent lateral incisors were buccally positioned, and 65.28% were palatally positioned. While 45.58% of sector I impacted maxillary canines were buccally positioned, 68.31% of sector IV impacted maxillary canines were palatally positioned. Furthermore, there was a statistical significance between the mesiodistal position and palatal or buccal maxillary canine impaction ( $p < 0.05$ ). In addition, the vertical position of the impacted maxillary canines was also related to their mesiodistal and buccopalatal positions ( $p < 0.05$ ).

*Conclusion:* While all maxillary impacted canines had the potential to cause lateral incisor resorption, there was no close relationship related to the canine's buccopalatal, mesiodistal and vertical position. Nevertheless, if an impacted maxillary canine migrated towards the midline, the buccopalatal and vertical position of the tooth changed from buccal to palatal and cervical to apical, respectively.

(Aust Orthod J 2020; 36: 160-167)

Received for publication: February 2020

Accepted: September 2020

Hakan Yilmaz: hakanyilmaz90@gmail.com; Fethiye Cakmak Ozlu: ckfethiye@hotmail.com; Murat Icen: dtmuraticen@gmail.com; Erdi Icen: erdiicen@gmail.com.

## Introduction

The permanent canines aid in the appearance of an aesthetically pleasing smile and have an important role in functional occlusion.<sup>1,2</sup> Maxillary canines are the second most commonly impacted teeth after the third molars,<sup>3,4</sup> with an incidence of 1–3%,<sup>5-7</sup> and with twice the prevalence in females compared with males.<sup>3,4</sup> Impacted canines can cause aesthetic problems related to tipping of adjacent teeth and midline deviations. They can also result in migration of adjacent teeth, cyst formation, pain and infection.<sup>3,8</sup>

However, the most common significant problem is root resorption of adjacent teeth,<sup>8-11</sup> particularly affecting the root of the maxillary lateral incisor.<sup>12,13</sup> Although less common, resorption may also affect the roots of the central incisors and premolars.<sup>14</sup> Ensuring the correct positioning of impacted canines in the dentoalveolar arch with surgical exposure and orthodontic treatment is clinically difficult and time-consuming.<sup>1,12,15</sup> Appropriate surgical intervention and orthodontic management depends on the accurate spatial localisation of the impacted teeth.<sup>1,7,16</sup>

Numerous theories and aetiological factors have been reported in relation to impacted maxillary canines.<sup>17-19,8</sup> Previous authors have proposed a guidance theory to explain how maxillary canines become palatally impacted due to the loss of guidance of a malformed or missing lateral incisor.<sup>20-23</sup> Another view, named the genetic theory, is identified when missing premolars, third molars or supernumerary teeth, also occur in company with the palatal impaction of a maxillary canine.<sup>24,25</sup> These theories are indirectly supported by studies indicating that patients with palatal maxillary canine impaction often have sufficient space for canine eruption.<sup>4,8,26</sup> Conversely, buccally impacted maxillary canines are commonly thought to be associated with dental crowding or skeletal (premaxillary) defects.<sup>8,27-29</sup>

In addition to the buccopalatal location of impacted maxillary canines, a mesiodistal location evident on panoramic radiographs may help estimate the duration and difficulty of treatment.<sup>30,31</sup> As the canine crown approaches the maxillary midline, the possibility of uneventful eruption after the removal of the primary canine is low.<sup>15</sup> Radiographically, if the cusp of the maxillary canine lies distal to the middle of the lateral incisor root, the likelihood of eruption of the canine after its deciduous precursor is removed is approximately 90%. The success rate of eruption decreases to 64% if the canine has passed the middle of the lateral incisor root.<sup>15</sup> It has been reported that when the maxillary canines are vertically located in the mid-third, resorption of the lateral incisors is more likely.<sup>15</sup>

Generally, two-dimensional (2D) radiographs are taken as part of an initial diagnosis, to locate the canines, to assess tooth eruption, to assist in treatment planning and to evaluate the results of treatment.<sup>2,32,33</sup> However, diagnostic information obtained from panoramic radiographs may be limited because of distortion, magnification, artefacts, blurred images and overlapping structures.<sup>2,32,34</sup> Panoramic radiographs are not reliable for evaluating root resorption on the palatal or buccal surfaces of the teeth or if the resorption is mild.<sup>35</sup> Cone beam computed tomography (CBCT) does not normally present these limitations.<sup>36,37</sup> Three-dimensional (3D) information can be obtained at high resolution from CBCT scans, while the level of radiation can be significantly less than that of a conventional CT.<sup>36,38</sup>

The aim of the present study was to investigate the effect of different 3D positions of impacted maxillary

canines on lateral incisor morphology (root length, width, and depth) and the incidence of root resorption.

## Material and method

### *Patients*

The study material was obtained from the records of patients who presented and were treated for impacted maxillary canines in the Orthodontic Department of the Dentistry Faculty of Zonguldak Bülent Ecevit University from 2014–2019. The demographic description of the population of this retrospective study was obtained from the Western Black Sea Region of Turkey. In addition to a routine orthodontic examination and records, a CBCT scan was taken with the informed consent of the patient, parent or legal guardian to obtain more information regarding the location of the maxillary canines and their effect on the anterior teeth. From the records obtained, and after the exclusion of patients with congenitally missing lateral incisors, cleft lip-palate, odontoma, mesiodens, and those with a syndrome or systemic disorder affecting the teeth and surrounding tissue, a total of 169 patients were included in the study. The patients comprised 73 females and 96 males with a mean age of  $17.91 \pm 6.52$  years (range, 11.66–40.25 years).

Approval for the study was granted by the Ethics Committee of Zonguldak Bülent Ecevit University Medical Faculty (protocol no: 215-119-18/11).

### *Method*

The patients were positioned standing with the head and Frankfort horizontal plane (alaris - tragus) parallel to the floor. CBCT images were acquired using a Veraviewepocs 3D R100 / F40 device (J Morita Manufacturing Corporation, Kyoto, Japan) applied at a tube voltage of 85-90kV, a tube current of 3-8mA, a scan duration of 9.4 seconds and FOV of  $8 \times 5$  cm and  $4 \times 4$  cm. After reconstruction of the scans, CBCT images were evaluated using i-Dixel 2.0 software (J. Morita Corporation, Osaka, Japan).

The impacted maxillary canines were classified in three groups as buccopalatal, mesiodistal and vertical according to crown position. A modification of the sectors described by Ericson and Kurol was used on the CBCT images to determine the mesiodistal position of the teeth.<sup>39</sup> Defining a reference point

as the lateral incisor, the impacted maxillary canines were classified according to their distance from the midline. To do this, three lines were drawn relative to the lateral incisors, and described by:

1. A line contacting the distal of the crown and root of the lateral incisor
2. A line dividing the lateral incisor by passing through the centre of the tooth's long axis
3. A line contacting the mesial of the crown and root of the lateral incisor.

Using the three constructed lines, four regional sectors were formed (Figure 1). The location of the cusp tip of the impacted maxillary canine was determined in relation to the created sectors, which were labelled as I, II, III, or IV. The vertical position of the impacted canine was determined as cervical, middle, or apical relative to the ipsilateral central incisor on the CBCT images.<sup>40</sup> Two oriented horizontal planes were drawn through the root apex of the central incisor and another passing through the cemento-enamel junction. After constructing the two lines, a third horizontal line was drawn parallel and equidistant. By dividing the root of the ipsilateral central incisor into three equal parts, vertical zones were derived (cervical, middle, apical). The vertical position of the cusp of an impacted maxillary canine was classified according to the defined zones. In addition, impacted maxillary canines were separated into two groups as palatal or buccal according to their location relative to the alveolar crest.

To determine the status of the teeth adjacent to the impacted maxillary canines, an analysis was undertaken of the mesiodistal and buccopalatal dimensions at the cemento-enamel junction, root length and resorption of the lateral incisors.

### Statistical analysis

Data obtained in the study were statistically analysed using IBM SPSS version 24.0 software (IBM Corporation, NY, USA). Conformity of the data to a normal distribution was assessed with Skewness, Kurtosis and the Shapiro-Wilk tests. To analyse mean differences within groups of data with a normal distribution, the Independent *t*-test and ANOVA were applied, and for those not showing a normal distribution, the Mann-Whitney *U*-test and the Kruskal-Wallis test were used. For comparisons

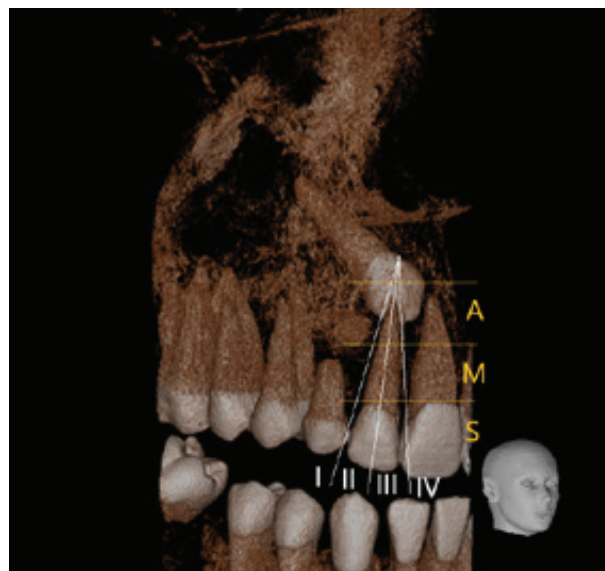


Figure 1. Mesiodistal sectors (I, II, III, IV) and vertical zones (C, M, A) of impacted maxillary canine on CBCT according to locations.

between groups and correlations, the Chi-square test and Fisher's Exact test were applied. A value of  $p < 0.05$  was accepted as statistically significant.

### Results

The statistics describing the age and gender of the study participants, the mesiodistal, buccopalatal dimensions of the adjacent lateral incisors at the cemento-enamel junction and root length, resorption in the lateral incisors, and buccopalatal, mesiodistal and vertical positions of the maxillary canines, are shown in Table I.

The relationships were examined between the root dimensions of the lateral incisors adjacent to maxillary canines with buccal or palatal impaction, the presence of resorption in the lateral incisor, and the mesiodistal and vertical locations of the maxillary canines. As presented in Table II, there was a statistically significant change in the mesiodistal and vertical positions according to the buccal or palatal displacement of the impacted maxillary canines ( $p < 0.01$ ).

The relationships of the mesiodistal location of the impacted maxillary canines according to the four sectors are shown in Table III. Root length and width variability was observed related to the adjacent lateral incisors, and a significant difference was determined in the buccopalatal and vertical location of the maxillary canines ( $p < 0.05$ ). As the impacted maxillary canines approached the midpalatal line (i.e., sector IV), there

**Table I.** Descriptive statistics of results.

	<i>N</i>	<i>Minimum</i>	<i>Maximum</i>	<i>Mean ± SD</i>	<i>SE</i>
<i>Age (years)</i>	169	11.66	40.25	17.91 ± 6.52	0.5
<i>Lat. M-D root width</i>	169	4.1	7.4	5.26 ± 0.61	0.05
<i>Lat. B-P root width</i>	169	4.26	8.96	6.11 ± 0.71	0.06
<i>Lat. root length</i>	169	4.14	17.80	13.86 ± 2.33	0.18
<i>Gender</i>		Female		Male	
	169	73 (43.2%)		96(56.8%)	
<i>Resorption in the lateral incisor</i>		<i>Present</i>		<i>Absent</i>	
	169	72(42.6%)		97(57.4%)	
<i>Canine B-P Position</i>		<i>Buccal</i>		<i>Palatal</i>	
	169	68(40.2%)		101(59.8%)	
<i>Canine M-D Sector</i>		<i>I</i>	<i>II</i>	<i>III</i>	<i>IV</i>
	169	43(25.44%)	14(8.28%)	30(17.75%)	82(48.52%)
<i>Canine vertical zone</i>		<i>Cervical</i>	<i>Median</i>	<i>Apical</i>	
	169	52 (30.8%)	61(36.1%)	56 (33.1%)	

SD: standard deviation, SE: standard error of mean

**Table II.** Comparisons of the groups according to buccopalatal position of the impacted canines.

		Buccal (N=68)	Palatal (N=101)	
<i>Values</i>		<i>Mean ± SD</i>	<i>Mean ± SD</i>	<i>p</i>
<i>Lateral incisor M-D root width</i>		5.23±0.46	5.28±0.7	0.61†
<i>Lateral incisor B-P root width</i>		6.32±0.87	5.97±0.55	0.014††
<i>Lateral incisor root length</i>		14.36±1.93	13.50±2.52	0.12††
		Buccal (N=68)	Palatal (N=101)	
<i>Lateral incisor resorption</i>	<i>Present</i>	25 (14.7%)	47(27.81%)	0.08†††
	<i>Absent</i>	43 (25.44%)	54(31.95%)	
<i>Canine M-D sector</i>	<i>I</i>	31(18.3%)	12(7.1%)	<0.01††††
	<i>II</i>	11(6.51%)	3 (1.78%)	
	<i>III</i>	13(7.69%)	17(10.6%)	
	<i>IV</i>	13(7.69%)	69(40.83%)	
<i>Canine vertical zone</i>	<i>C</i>	31(18.34%)	21(12.43%)	<0.01††††
	<i>M</i>	8(4.7%)	53(31.4%)	
	<i>A</i>	29(17.16%)	27(15.98%)	

† Student *t* test, †† Mann Whitney *U* test, ††† Fisher exact test, †††† Chi-Square test

was an increase in either the palatal or apical position. However, if the impacted maxillary canines were closer to sector I, the likelihood of buccal or cervical displacement was increased. In addition, the chance of lateral incisor resorption increased when the impacted maxillary canines approached the midpalatal line ( $p < 0.05$ ).

As presented in Table IV, lateral incisor resorption was unrelated to the vertical location of the impacted maxillary canine. However, the buccopalatal and mesiodistal position of an impacted maxillary canine was affected by its vertical location ( $p < 0.05$ ).

**Table III.** Comparison of the groups according to mesiodistal location of the impacted canines.

		Sector I (N=43)	Sector II (N=14)	Sector III (N=30)	Sector IV (N=82)	<i>p</i>
Values		Mean ± SD	Mean ± SD	Mean ± SD	Mean ± SD	
Lateral incisor M-D root width		5.18±0.34	5.29±0.5	5.27±0.47	5.31±0.77	0.72†
Lateral incisor B-P root width		6.36±0.5	6.99±1.46	5.90±0.43	5.92±0.61	<0.05††
Lateral incisor root length		14.17±1.84	13.61±0.67	15.24±2.43	13.17±2.44	<0.05††
		Sector I (N=43)	Sector II (N=14)	Sector III (N=30)	Sector IV (N=82)	<i>p</i>
Lateral incisor resorption	Present	10(5.91%)	9(5.32%)	7(4.14%)	46(27.22%)	<0.05†††
	Absent	33(19.52%)	5(2.96%)	23(13.61%)	36(21.3%)	
Canine B-P position	B	31(18.3%)	11(6.51%)	13(7.69%)	13(7.69%)	<0.01†††
	P	12(7.1%)	3(1.78%)	17(10.6%)	69(40.83%)	
Canine vertical zone	C	23(13.61%)	5(2.96%)	10(5.92%)	14(8.28%)	<0.01†††
	M	16(9.47%)	2(1.18%)	9(5.33%)	34(20.12%)	
	A	3(1.78%)	8(4.73%)	11(6.51%)	34(20.11%)	

† ANOVA test, †† Kruskal-Wallis test, ††† Chi-Square test

## Discussion

The resorption of anterior teeth in the presence of impacted maxillary canines occurs and is of concern to patients and clinicians.<sup>12</sup> The incidence of root resorption affecting the lateral incisors adjacent to impacted maxillary canines was found to be 42.6% in the present study. Root resorption rates examined by different imaging methods reportedly vary in incidence between 6% and 67%,<sup>9,15,37</sup> and studies that have previously examined the prevalence of lateral incisor resorption using CBCT reported inconsistencies. Liu et al.<sup>16</sup> noted a resorption rate of 27% in lateral incisors adjacent to 210 impacted maxillary canines, while Walker et al.<sup>7</sup> reported a prevalence of 66.7% in 27 cases. Kim et al.<sup>29</sup> reported a prevalence of 49.5% in a study of 186 impacted maxillary canines. The reasons for the variation were likely related to different age ranges of the patients and operator experience in interpreting CBCT images.<sup>16</sup> The resorption incidence rates have also been reported to be related to the imaging technique used.<sup>2</sup>

The results of the current study revealed no significant relationship between the buccopalatal position of impacted maxillary canines and root resorption of the lateral incisors ( $p > 0.05$ ). Recent studies have compared canines presenting with buccal and palatal impaction against control groups.<sup>10,11,35</sup> However, there are conflicting results. Kim et al. reported that impacted maxillary canines in a buccal

position caused more resorption in adjacent teeth than those in palatal positions and the relationship was statistically significant.<sup>29</sup> In contrast, Lai et al. observed more root resorption when maxillary canines were in a buccal position but the difference was not statistically significant.<sup>10</sup> Ucar et al. described more root resorption in the lateral incisors associated with palatally impacted maxillary canines compared with those canines impacted in a buccal position. There was, however, no noted statistical significance.<sup>11</sup> As these studies were conducted in different geographic regions, the differences in the results could be attributed to demographic variability as it has been previously reported that the variability of a population influences the incidence of resorption in any tooth or individual in relation to displaced maxillary canines.<sup>13</sup>

When comparing impacted maxillary canines according to the four sectors of mesiodistal location, it was noted that the lateral incisor resorption rate increased with greater canine proximity to the maxillary midline. The difference, however, was not statistically significant ( $p > 0.05$ ). Similarly, Ucar et al. compared the sectors in which the canines were localised and, although the amount of lateral root resorption increased from sector I to sector IV, the difference was again not statistically significant.<sup>11</sup> Ngo et al. evaluated the relationship between the sector location of the maxillary canines and root resorption and, while no root resorption of the lateral incisors was

Table IV. Comparison of the groups according to the vertical position of the impacted canines.

		Cervical (N=52)	Middle (N=61)	Apical (N=56)	
Values		Mean ± SD	Mean ± SD	Mean ± SD	<i>p</i>
Lateral incisor M-D root width		5.21±0.58	5.34±0.67	5.23±0.57	0.49†
Lateral incisor B-P root width		6.09±0.68	6.15±0.48	6.08±0.93	0.25††
Lateral incisor root length		13.77±2.11	13.77±2.94	14.03±1.74	0.72††
Values		Cervical (N=52)	Middle (N=61)	Apical (N=56)	<i>p</i>
Lateral incisor resorption	Present	21(12.43%)	27(15.976%)	24(14.2%)	0.7†††
	Absent	33(19.53%)	33(19.53%)	31(18.34%)	
Canine B-P position	B	31(18.34%)	8(4.7%)	29(17.16%)	<0.01†††
	P	21(12.43%)	53(31.4%)	27(15.98%)	
Canine M-D sector	I	23(13.61%)	16(9.47%)	3(1.78%)	<0.01†††
	II	5(2.96%)	2(1.18%)	8(4.73%)	
	III	10(5.92%)	9(5.33%)	11(6.51%)	
	IV	14(8.28%)	34(20.12%)	34(20.11%)	

† ANOVA test, †† Kruskal-Wallis test, ††† Chi-Square test

determined in sectors I, II, and III, root resorption was observed in 21 of 39 teeth in sectors IV and V.<sup>33</sup> It has also been reported that impacted maxillary canines in sector I indicate buccal impaction and those located in sectors IV and V suggest palatal impaction.<sup>33</sup> Lindauer et al. reported that when most of the tip of the cusp of the maxillary canine was displaced to the mesial or over the lateral incisor root, palatal impaction of the maxillary canine was indicated.<sup>39</sup> Kim et al. analysed the position of impacted maxillary canines, and, consistent with the present study, found that buccally impacted canines were more frequent in sector II, whereas palatally impacted canines were more frequent in sector IV.<sup>31</sup> The findings of the current study indicated that palatal rather than buccal impaction was seen more often when canine location was noted from sector I towards sector IV, in results that were found to be statistically significant ( $p < 0.05$ ).

In previous studies that have used two-dimensional radiographs to determine the vertical positioning of impacted maxillary canines, resorption of the lateral incisors has been reported to be 82% in the mid-third, 13% in the apical, and the remainder in the cervical areas of the tooth root.<sup>15</sup> More recent studies that have used CT have reported that most maxillary lateral incisor root resorption is located in the mid-

third, thereby confirming previous research.<sup>10,12</sup> In the current study, no statistically significant relationship was determined between the vertical position of impacted maxillary canines and lateral incisor root resorption ( $p > 0.05$ ). However, the vertical position of an impacted maxillary canine had a statistical relationship with the mesiodistal sectors and buccopalatal positions ( $p < 0.05$ ). According to these results, while canines positioned in sector I were mostly impacted near the cervical, canines in sector IV were located near the apical area.

There is a relationship between impacted maxillary canines and morphological anomalies of maxillary lateral incisors.<sup>3,20</sup> Liuk et al. assessed the mean length, width (mesiodistal) and depth (buccopalatal) values of upper lateral incisors adjacent to palatally impacted maxillary canines and found these parameters were lower than those of a control group.<sup>23</sup> Through examination of periapical and panoramic radiographs, Becker et al. also found the mean length of upper lateral incisors adjacent to palatally impacted canines was shorter than the dimensions of a control group.<sup>22</sup> Becker reported that the mean length of the lateral incisor was approximately 6 mm longer than that reported by Liuk et al. As confirmed by a previous study, this demonstrates that CBCT measurements are likely more accurate and reliable.<sup>36</sup>

In a study that compared the mesiodistal and buccopalatal root width of maxillary lateral incisors of individuals with buccally or palatally impacted canines, the mesiodistal width of lateral incisors associated with buccally impacted canines tended to be greater, whereas no difference was observed in buccopalatal width.<sup>28</sup> In the current study, no statistically significant difference was apparent in the root width, length and depth of lateral incisors adjacent to buccally or palatally impacted maxillary canines. A possible reason for this difference could be that most studies did not compare the lateral incisors adjacent to palatally or buccally impacted maxillary canines with each other but only to a control group.

One of the main aims of the current study was to evaluate the position of impacted maxillary canines in the three planes of space (sagittal, vertical and horizontal) using a reliable and repeatable method. Conventional radiographs are known to have limitations related to overlapping images, misinterpretation of palatal and buccal canine location, magnification and distortion.<sup>2,32,34</sup> As CBCT scans can provide accuracy in all spatial planes in describing the position and dimensions of impacted maxillary canines, this method was used in the current study. However, the classification of canine position was made using methods previously employed on panoramic radiographs introduced by Ericson and Kuroi<sup>35</sup> and later developed by Lindauer.<sup>39</sup> By this universal classification, it was possible to compare the results of CBCT scans with other imaging methods, consistent with previous studies that have examined impacted maxillary canine position by using CBCT.<sup>29,33</sup>

In light of the results of the present study, it is recommended that clinicians take into consideration the high probability of resorption of the adjacent lateral incisors when the mesiodistal location of an impacted maxillary canine enters sector IV, and diagnosis and treatment planning should be made accordingly. Clinicians should also be aware that the mesiodistal location (sector) of an impacted maxillary canine on 2D radiographs may be used to estimate buccopalatal and vertical positions. In addition, while panoramic radiographs may be sufficient for the sector and vertical zone analyses of impacted maxillary canines, the level of resorption and buccopalatal displacement should be examined by CBCT.

## Conclusions

Within the scope of the present study, it was concluded that:

- As the mesiodistal position of an impacted maxillary canine locates from sector I to sector IV towards the midpalatal line, its buccopalatal position changes from buccal towards the palatal and the vertical position from cervical to apical.
- The resorption frequency in adjacent lateral incisors was higher when an impacted maxillary canine was either located in sector IV in the mesiodistal plane or on the palatal side in the buccopalatal plane.
- There was no significant difference between buccally and palatally impacted maxillary canines in respect of the mean root length and width of the lateral incisors.

## Conflict of interest

The authors report no professional or financial conflict of interest in relation to this study.

## Corresponding author

Hakan Yilmaz  
Department of Orthodontics  
Faculty of Dentistry  
Istanbul Okan University  
Istanbul  
Turkey  
Email: hakanyilmaz90@gmail.com

## References

1. Rossini G, Cavallini C, Cassetta M, Galluccio G, Barbato E. Localization of impacted maxillary canines using cone beam computed tomography. Review of the literature. *Ann Stomatol (Roma)* 2012;3:14-8.
2. Wriedt S, Jaklin J, Al-Nawas B, Wehrbein H. Impacted upper canines: examination and treatment proposal based on 3D versus 2D diagnosis. *J Orofac Orthop* 2012;73:28-40.
3. Becker A, Smith P, Behar R. The incidence of anomalous maxillary lateral incisors in relation to palatally-displaced cuspids. *Angle Orthod* 1981;51:24-9.
4. Peck S, Peck L, Kataja M. The palatally displaced canine as a dental anomaly of genetic origin. *Angle Orthod* 1994;64:249-56.
5. Mason C, Papadakou P, Roberts GJ. The radiographic localization of impacted maxillary canines: a comparison of methods. *Eur J Orthod* 2001;23:25-34.
6. Preda L, La Fianza A, Di Maggio EM, Dore R, Schifino MR, Campani R et al. The use of spiral computed tomography in the

- localization of impacted maxillary canines. *Dentomaxillofac Radiol* 1997;26:236-41.
7. Walker L, Enciso R, Mah J. Three-dimensional localization of maxillary canines with cone-beam computed tomography. *Am J Orthod Dentofacial Orthop* 2005;128:418-23.
  8. Jacoby H. The etiology of maxillary canine impactions. *Am J Orthod* 1983;84:125-32.
  9. Ericson S, Kurol J. Incisor root resorptions due to ectopic maxillary canines imaged by computerized tomography: a comparative study in extracted teeth. *Angle Orthod* 2000;70:276-83.
  10. Lai CS, Bornstein MM, Mock L, Heuberger BM, Dietrich T, Katsaros C. Impacted maxillary canines and root resorptions of neighbouring teeth: a radiographic analysis using cone-beam computed tomography. *Eur J Orthod* 2013;35:529-38.
  11. Ucar FI, Celebi AA, Tan E, Topcuoğlu T, Sekerci AE. Effects of impacted maxillary canines on root resorption of lateral incisors. *J Orofac Orthop* 2017;78:233-40.
  12. Ericson S, Kurol PJ. Resorption of incisors after ectopic eruption of maxillary canines: a CT study. *Angle Orthod* 2000;70:415-23.
  13. Sameshima GT, Sinclair PM. Predicting and preventing root resorption: Part I. Diagnostic factors. *Am J Orthod Dentofacial Orthop* 2001;119:505-10.
  14. Alqerban A, Jacobs R, Lambrechts P, Loozen G, Willems G. Root resorption of the maxillary lateral incisor caused by impacted canine: a literature review. *Clin Oral Invest* 2009;13:247-55.
  15. Ericson S, Kurol J. Radiographic examination of ectopically erupting maxillary canines. *Am J Orthod Dentofacial Orthop* 1987;91:483-92.
  16. Liu D-g, Zhang W-l, Zhang Z-y, Wu Y-t, Ma X-c. Localization of impacted maxillary canines and observation of adjacent incisor resorption with cone-beam computed tomography. *Oral Surg Oral Med Oral Pathol Oral Radiol Endod* 2008;105:91-8.
  17. Bishara SE. Impacted maxillary canines: a review. *Am J Orthod Dentofacial Orthop* 1992;101:159-71.
  18. Jacobs SG. The impacted maxillary canine. Further observations on aetiology, radiographic localization, prevention/interception of impaction, and when to suspect impaction. *Aust Dent J* 1996;41:310-6.
  19. Litsas G, Acar A. A review of early displaced maxillary canines: etiology, diagnosis and interceptive treatment. *Open Dent J* 2011;5:39-47.
  20. Brin I, Becker A, Shalhav M. Position of the maxillary permanent canine in relation to anomalous or missing lateral incisors: a population study. *Eur J Orthod* 1986;8:12-6.
  21. Becker A. In defense of the guidance theory of palatal canine displacement. *Angle orthod* 1995;65:95-8.
  22. Becker A, Zilberman Y, Tsur B. Root length of lateral incisors adjacent to palatally-displaced maxillary cuspids. *Angle orthod* 1984;54:218-25.
  23. Liuk IW, Olive RJ, Griffin M, Monsour P. Maxillary lateral incisor morphology and palatally displaced canines: a case-controlled cone-beam volumetric tomography study. *Am J Orthod Dentofacial Orthop* 2013;143:522-6.
  24. Peck S, Peck L, Kataja M. Concomitant occurrence of canine malposition and tooth agenesis: evidence of orofacial genetic fields. *Am J Orthod Dentofacial Orthop* 2002;122:657-60.
  25. Pirinen S, Arte S, Apajalahti S. Palatal displacement of canine is genetic and related to congenital absence of teeth. *J Dent Res* 1996;75:1742-6.
  26. Zilberman Y, Cohen B, Becker A. Familial trends in palatal canines, anomalous lateral incisors, and related phenomena. *Eur J Orthod* 1990;12:135-9.
  27. Thilander B, Jakobsson SO. Local factors in impaction of maxillary canines. *Acta Odontol Scand* 1968;26:145-68.
  28. Chaushu S, Sharabi S, Becker A. Tooth size in dentitions with buccal canine ectopia. *Eur J Orthod* 2003;25:485-91.
  29. Kim Y, Hyun H-K, Jang K-T. The position of maxillary canine impactions and the influenced factors to adjacent root resorption in the Korean population. *Eur J Orthod* 2012;34:302-6.
  30. Stewart JA, Heo G, Glover KE, Williamson PC, Lam EW, Major PW. Factors that relate to treatment duration for patients with palatally impacted maxillary canines. *Am J Orthod Dentofacial Orthop* 2001;119:216-25.
  31. Kim S-H, Son W-S, Yamaguchi T, Maki K, Kim S-S, Park S-B et al. Assessment of the root apex position of impacted maxillary canines on panoramic films. *Am J Orthod Dentofacial Orthop* 2017;152:489-93.
  32. Elefteriadis JN, Athanasiou AE. Evaluation of impacted canines by means of computerized tomography. *Int J Adult Orthodon Orthognath Surg* 1996;11:257-64.
  33. Ngo CT, Fishman LS, Rossouw PE, Wang H, Said O. Correlation between panoramic radiography and cone-beam computed tomography in assessing maxillary impacted canines. *Angle Orthod* 2018;88:384-9.
  34. Yeo DK, Freer TJ, Brockhurst PJ. Distortions in panoramic radiographs. *Aust Orthod J* 2002;18:92-8.
  35. Ericson S, Kurol J. Resorption of maxillary lateral incisors caused by ectopic eruption of the canines: a clinical and radiographic analysis of predisposing factors. *Am J Orthod Dentofacial Orthop* 1988;94:503-13.
  36. Baumgaertel S, Palomo JM, Palomo L, Hans MG. Reliability and accuracy of cone-beam computed tomography dental measurements. *Am J Orthod Dentofacial Orthop* 2009;136:19-25.
  37. Mah JK, Alexandroni S. Cone-beam computed tomography in the management of impacted canines. *Semin Orthod* 2010;16:199-204.
  38. Mah JK, Danforth RA, Bumann A, Hatcher D. Radiation absorbed in maxillofacial imaging with a new dental computed tomography device. *Oral Surg Oral Med Oral Pathol Oral Radiol Endod* 2003;96:508-13.
  39. Lindauer SJ, Rubenstein LK, Hang WM, Andersen WC, Isaacson RJ. Canine impaction identified early with panoramic radiographs. *J Am Dent Assoc* 1992;123:91-7.
  40. Nagpal A, Pai KM, Setty S, Sharma G. Localization of impacted maxillary canines using panoramic radiography. *J Oral Sci* 2009;51:37-45.